



Internationally indexed journal

Indexed in Chemical Abstract Services (USA), Index copernicus, Ulrichs Directory of Periodicals, Google scholar, CABI ,DOAJ , PSOAR, EBSCO , Open J gate , Proquest , SCOPUS , EMBASE ,etc.



Rapid and Easy Publishing

The "International Journal of Pharma and Bio Sciences" (IJPBS) is an international journal in English published quarterly. The aim of IJPBS is to publish peer reviewed research and review articles rapidly without delay in the developing field of pharmaceutical and biological sciences



Pharmaceutical Sciences

- Pharmaceutics
- Novel drug delivery system
- Nanotechnology
- Pharmacology
- Pharmacognosy
- Analytical chemistry
- Pharmacy practice
- Pharmacogenomics



Biological Sciences

- Polymer sciences
- Biomaterial sciences
- Medicinal chemistry
- Natural chemistry
- Biotechnology
- Pharmacoinformatics
- Biopharmaceutics
- Biochemistry
- Biotechnology
- Bioinformatics
- Cell biology
- Microbiology
- Molecular biology
- Neurobiology
- Cytology
- Pathology
- Immunobiology

**Indexed in Elsevier Bibliographic Database
(Scopus and EMBASE)**

SCImago Journal Rank 0.288

Impact factor 5.121*

Chemical Abstracts
Service (www.cas.org)



A division of the American Chemical Society

CODEN IJPBJ2



Elsevier Bibliographic databases (Scopus & Embase)

SNIP value – 0.77

SJR - 0.288

IPP - 0.479

SNIP – Source normalised impact per paper

SJR – SCImago Journal rank

IPP – Impact per publication

Source – www.journalmetrics.com

(Powered by scopus (ELSEVIER))



LUND
UNIVERSITY



JACKSONVILLE STATE UNIVERSITY

Jacksonville State University
Houston Cole Library
USA (Alabama)



UNIVERSITY OF
OXFORD

Oxford, United Kingdom



*And indexed/catalogued in
many more university*



*Instruction to Authors visit www.ijpbs.net

For any Queries, visit "contact" of www.ijpbs.net

**ASSESSING THE DIMENSION OF SACRAL SPINAL
CANAL FOR THECALOSCOPY USING MRI****ABHIMANYU PRADHAN*¹ AND SUSHIL YADAV²**¹ Assistant Professor, Dept. of Medical Imaging Technology, School of Allied Health Sciences, Manipal University, Manipal² Assistant Professor (Sr. Scale) Dept. of Medical Imaging Technology School of Allied Health Sciences Manipal University, Manipal**ABSTRACT**

Endoscopy of the lumbar sub-arachnoidal space is named thecaloscopy, which has been used for diagnostic and therapeutic purposes. The understanding of the anatomic dimensions of this region is useful for the atraumatic use of flexible endoscopes. Furthermore, by using MRI the determination of anatomic values of the sacral spinal canal is possible without the use of cadaver measurements. MRI of lumbo-sacral region was performed on 25 male and 25 female patients who were referred by treating doctor. Measurements were performed on T2 weighted mid-sagittal image. The dimensions measured were sacral Spinal Canal (SSC), Sacral Spinal Process (SSP) and the width of sacral hiatus. The mean length of sacral spinal canal in its center for male was 76.34 ± 5.091 (range 67.8-91) and for female was 74.276 ± 6.775 (range 59.8-86.7). The mean length of the sacral spinal process for male was 70.608 ± 5.861 (range 55.1-88.0) and for female was 67.592 ± 7.436 (range 53.6-82.3). The width of sacral hiatus was 17.32 ± 1.730 mm for male and 17.08 ± 1.868 mm for female. Also the Lumbar Sacral Angle were measured whose mean for female was 61.28 ± 8.681 and for male was 53.24 ± 6.488 . Trans-sacral endoscopy though sacral hiatus is anatomically possible to perform because the endoscope can be introduced through the sacral hiatus over a length of sacral spinal canal. No further means needs to be undertaken during thecaloscopy, since the difference between sexes for the measured diameters is not statistically significant.

KEYWORDS: Lumbo-sacral angle, Thecaloscopy, Subarachnoid**ABHIMANYU PRADHAN**Assistant Professor, Dept. of Medical Imaging Technology,
School of Allied Health Sciences, Manipal University, Manipal

*Corresponding author

INTRODUCTION

At least once in their life two thirds of the adult populations are affected by back pain. This pain is usually described by the patients in lower lumbar spine and/or of the lumbosacral transition¹. Back complaints, mainly in the form of lumbo-ischiatic pain, have turned to be the most expensive musculoskeletal diseases in the industrialized countries². Therefore there is large scientific interest in further diagnostics and therapy of these patients. New diagnostic and therapeutic methods have been developed which are minimal invasive neurosurgical procedures, such as neuro-endoscopy and thecaloscopy^{3, 4}. Endoscopy has a long history and is used extensively today following recent technical improvements. Endoscopy has been used in neurosurgery to examine ventricles, cisterns, and intra-arteries⁵. Endoscopy of the lumbar sub-arachnoid space is named thecaloscopy, which has been used for diagnostic and therapeutic purposes. According to the anatomical structures, namely the thecal sac and its anatomical position, the procedure is called thecaloscopy and the instrument is a thecaloscope. The understanding of the anatomic dimensions of this region is useful for the atraumatic use of flexible endoscopes. The aim of this study was the assessment of the dimension of Sacral Spinal Canal for Thecaloscopy using MRI, to evaluate the dimension of the sacral spinal canal. Furthermore, by

using MRI the determination of anatomic values of the sacral spinal canal is possible without the use of cadaver measurements.

MATERIALS AND METHODS

Approval was acquired from ethical committee of Kasturba Hospital and institution research committee, School of Allied Health Sciences. The study design followed is Perspective observational design, carried out in MRI 1.5 T GE, Department Of Radio-diagnosis and Imaging, Kasturba Hospital, Manipal, Karnataka. Samples collected were 50, equally distributed to 25 males and 25 females of age group between 20-60 years who were referred by a physician for MRI of lumbar sacral spine. MRI scan of the lumbar sacral region was performed using routine sequences. Measurements were performed in T2 weighted mid-sagittal image. Metric data were collected in millimeters which includes SSC, SSP and width of sacral hiatus. The data from the end of dural sac were also collected and also the LSA were measured in degree. The obtained data were tabulated and statistically analyzed using SPSS 16.0 where maximum and minimum values, range, means, standard deviation and 95% Confidence Interval of the mean were calculated. A probability value < 0.05 is considered to be statistically significance using Independent T-test.

Table I
Definition of anatomic parameters of the body of the first sacral vertebra (S1)

Sl.no	Parameters	Abbreviation	Definition
1	Lumbosacral angle	LSA	The angle between the anterior border of S1 vertebral body and that of the 5th lumbar vertebra.
2	Sacral spinal processes	SSP	The distance from the end of Dural sac to the inferior border of fifth sacral vertebra by drawing a horizontal line.
3	Sacral spinal canal	SSC	The distance from the end of Dural sac to the inferior border of fifth sacral vertebra.

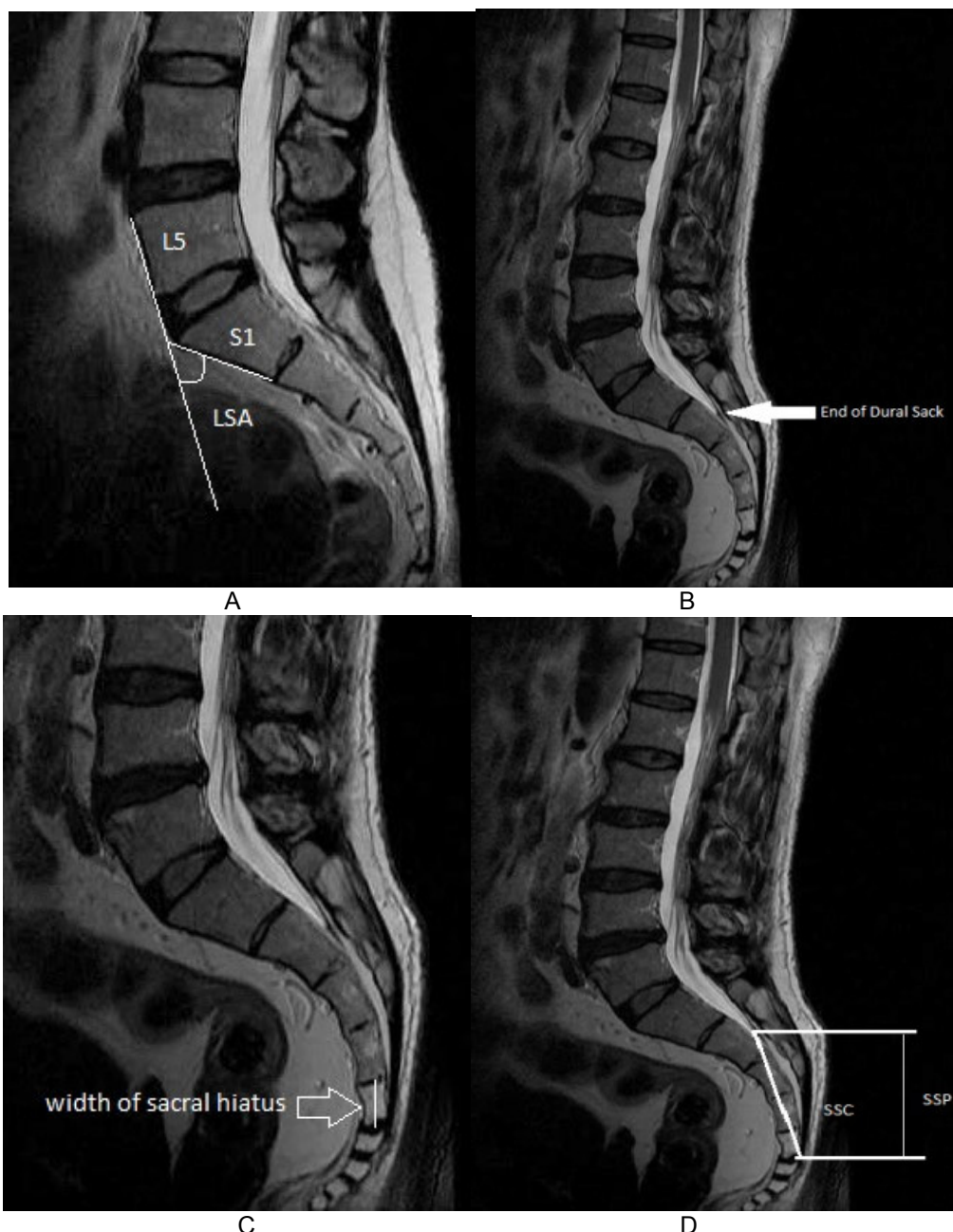


Figure I
Mid-sagittal MRI images identifying: A) Lumbosacral angle (LSA), B) End of dural sac C) width of sacral hiatus. D) Sacral spinal canal (SSC) and Sacral spinal process (SSP)

RESULTS

There were 25 males with a mean age of 41 years (range 24-60 years) and 25 females with a mean age of 42 years (range 23-59 years). The investigated data was summarized in the table no: II. The mean of lumbo-sacral angle (LSA) for female was 61.28 ± 8.681 and for male was 53.24 ± 6.488 . The end of the dural sack was located in the end of S2 vertebral body for 10 patients (20%), for 14 patients (28%) at the middle of the S2 vertebra, 4 patients (8%) in mid S1 and for 23 patients (46%) it was

located in End of S1 vertebra. The mean length of sacral spinal canal in its center for male was 76.34 ± 5.091 (range 67.8-91) and for female was 74.276 ± 6.775 (range 59.8-86.7). The mean length of sacral spinal process for male was 70.608 ± 5.861 (range 55.1-88.0) and for female was 67.592 ± 7.436 (range 53.6-82.3). The width of sacral hiatus was 17.32 ± 1.730 mm for male and 17.08 ± 1.868 mm for female. The data clearly states that the length of sacral spinal process is smaller than the length of the sacral spinal canal in its center (figure no: II).

Table II
Statistical analysis of the investigated measurement and indices in male and female

	Males (no. 25)			Females (no.25)			MGD	SE	CI	P-value
	Mean	SD	Range	Mean	SD	Range				
LSA	53.24	6.488	39-64	61.28	8.681	42-73	8.040	2.168	3.681to12.399	0.001
SSC	76.34	5.091	67.8-91	74.27	6.775	59.8-86.7	2.064	1.695	1.344to5.472	0.229
SSP	70.60	5.861	55.1-88.0	67.59	7.436	53.6-82.3	3.016	1.894	0.792to6.824	0.118
Sacral hiatus	17.32	1.730	13.2-20.6	17.08	1.868	14.7-21.1	0.240	0.509	0.784to1.264	0.640

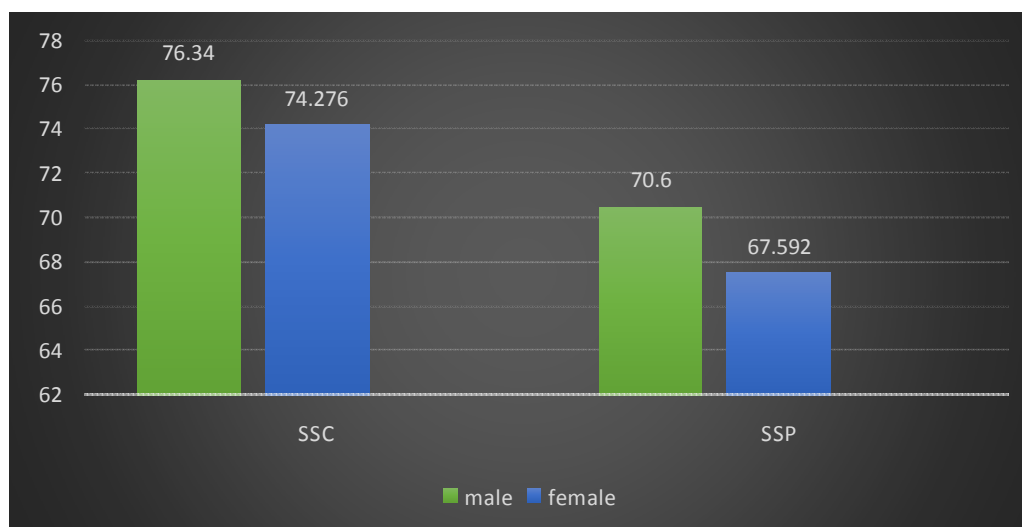


Figure II
A histogram showing the difference in sacral spinal canal and sacral spinal process.

DISCUSSION

Different diagnostic and therapeutic procedures have been developed in the latter twenty years. Great interest lies in minimal invasive methods, particularly in endoscopic procedures, which include extradural and intradural exploration techniques^{3, 7}. The LSA is considered as a theoretical reason for back pain⁶. Therefore in this study the LSA was measured to prove the anatomical possibility for trans-sacral endoscopy through the sacral hiatus. For the trans-sacral approach the length of all sacral spinal process, the end of dural sack and the width of the sacral hiatus are important. This study showed that the length of sacral spinal process is smaller than that of sacral spinal canal. Thus when the endoscope is directly employed under the sacral spinal process, it can be further manipulated without using the entire width of sacral spinal canal. Similar result was reported by Sofia⁶ in her study. Warnke J P et al.,⁸ conducted a study in which a 2.8-mm fiberoptic endoscope was used to insert into the thecal sac through transsacral approach. He found that the percutaneous insertion of a 2.8-mm endoscope into the

lumbar subarachnoid space was feasible without any neural structural damage. This study supports the result of the author as the width of the sacral hiatus (Table II) is much larger than the size of the endoscope used by the author. The dural sac ends at the level of S2 vertebra in 46% of the patients. The distance from the sacral hiatus to the dural sac's end, ranges from 35 to 75 mm, and is smaller if in cases the dural sac ends at a higher level. Finally the width of sacral hiatus is large enough in both sexes for the passage of the flexible endoscope. Also the LSA is easy to pass, because its angle range from 39° to 73°.

CONCLUSION

This study has shown that MRI is a reliable method for the measurement of different dimensions of the sacrum and lumbar region. The dimensions measured were analyzed and hence this study was concluded that the trans-sacral endoscopy i.e., thecaloscopy, can be easily performed with the guidance of MRI.

REFERENCES

1. Wiesel S.W., Weinstein J.N., Herkowitz H., Bell G. (Hrsg.): The lumbar spine, Vol. 2. Saunders, Philadelphia; 1065–1074, (1996)
2. Quinet R.J., Hadler N.M. Diagnosis and treatment of backache. Semin. Arthritis Rheum; 8: 261–287, (1979)

3. Heavner JF, Cholkhavatia S, Kizelshteyn G. Percutaneous evaluation of the epidural and subarachnoid space with flexible endoscope. *Reg. Anesth*; 15: S1: 85, (1991)
4. Sabreski L.R, Kitahata L.M. Direct visualization of the lumbosacral epidural space through the sacral hiatus. *Anest. Anal*; 60: 839–840, (1995)
5. Eguchi T., Tamaki N. Endoscopy of spinal cord and posterior fossa by a lumbar percutaneous approach: endoscopic anatomy in cadavers, 42(2):74-78, (1999)
6. Sofia M., Antomios S., Safia A. The dimensions of the sacral spinal canal in thecaloscopy: a morphometric MRI study. *Neuroanatomy* 8: 1-3, (2009)
7. Mourgela S., Anagnostopoulou S., Warnke J.P., Spanos A. Thecaloscopy through sacral bone approaches, cadavers study: further anatomic landmarks. *Minim. Invasive Neurosurg*; 49: 30–33, (2006)
8. Warnke J.P., Mourgela S., Tschabitscher M., Dzelzitis J. Thecaloscopy Part II: Anatomical Landmarks. *Minim. Invas. Neurosurg*; 44: 181–185, (2001)