



Internationally indexed journal

Indexed in Chemical Abstract Services (USA), Index copernicus, Ulrichs Directory of Periodicals, Google scholar, CABI ,DOAJ , PSOAR, EBSCO , Open J gate , Proquest , SCOPUS , EMBASE ,etc.



Rapid and Easy Publishing

The "International Journal of Pharma and Bio Sciences" (IJPBS) is an international journal in English published quarterly. The aim of IJPBS is to publish peer reviewed research and review articles rapidly without delay in the developing field of pharmaceutical and biological sciences



Pharmaceutical Sciences

- Pharmaceutics
- Novel drug delivery system
- Nanotechnology
- Pharmacology
- Pharmacognosy
- Analytical chemistry
- Pharmacy practice
- Pharmacogenomics



Biological Sciences

- Polymer sciences
- Biomaterial sciences
- Medicinal chemistry
- Natural chemistry
- Biotechnology
- Pharmacoinformatics
- Biopharmaceutics
- Biochemistry
- Biotechnology
- Bioinformatics
- Cell biology
- Microbiology
- Molecular biology
- Neurobiology
- Cytology
- Pathology
- Immunobiology

**Indexed in Elsevier Bibliographic Database
(Scopus and EMBASE)**

SCImago Journal Rank 0.288

Impact factor 2.958*

Chemical Abstracts
Service (www.cas.org)



A division of the American Chemical Society

CODEN IJPBJ2



Elsevier Bibliographic databases (Scopus & Embase)

SNIP value – 0.77

SJR - 0.288

IPP - 0.479

SNIP – Source normalised impact per paper

SJR – SCImago Journal rank

IPP – Impact per publication

Source – www.journalmetrics.com

(Powered by scopus (ELSEVIER))



LUND
UNIVERSITY



JACKSONVILLE STATE UNIVERSITY

Jacksonville State University
Houston Cole Library
USA (Alabama)



UNIVERSITY OF
OXFORD

Oxford, United Kingdom

INDEX COPERNICUS
INTERNATIONAL

*And indexed/catalogued in
many more university*



*Instruction to Authors visit www.ijpbs.net

For any Queries, visit "contact" of www.ijpbs.net



SURGICAL MANAGEMENT OF FRACTURE NECK OF FEMUR USING CANNULATED CANCELLOUS SCREWS IN PATIENTS AGED MORE THAN 50 YEARS

**DR. NAGAKUMAR. J. S¹, DR. SAMARTH ARYA*²,
DR. MANOHAR. P.V³ AND DR. B. SHAIKH NAZEER⁴**

¹ Associate Professor, Department of Orthopaedics, R.L.Jalappa Hospital and Research Centre, Tamaka, Kolar

^{*2} Jr. Resident, Department of Orthopaedics, R.L.Jalappa Hospital and Research Centre, Tamaka, Kolar

³ Professor and Head of the Department, Department of Orthopaedics,
R.L.Jalappa Hospital and Research Centre, Tamaka, Kolar

⁴ Professor, Department of Orthopaedics, R.L.Jalappa Hospital and Research Centre, Tamaka, Kolar

ABSTRACT

Fractures of the femoral neck are devastating injuries that most often affects the elderly and have a tremendous impact on the health care system and society in general. Patients who have presented with fracture neck of femur over the age of 60, but have been performing from a functional point of view as a younger individual have been excellent candidates for reduction with internal fixation. Several studies have suggested that reduction and fixation of an intracapsular fracture of the hip with multiple pins or screws is associated with a lower rate of morbidity and mortality than treatment with prosthetic replacement. We evaluated the results with respect to the efficacy of internal fixation by cannulated cancellous screw in terms of survival of the implants, complications, the survival of the patients, and the function of the patients in whom the fracture had healed without the development of osteonecrosis.

KEYWORDS: Fracture neck of femur, Intracapsular, Cannulatedcancellous screw, Osteonecrosis



DR. SAMARTH ARYA

Jr. Resident, Department of Orthopaedics, R.L. Jalappa Hospital
and Research Centre, Tamaka, Kolar

*Corresponding author

INTRODUCTION

Fractures of the femoral neck are devastating injuries that most often affects the elderly and have a tremendous impact on the health Care system and society in general. The worldwide incidence of femoral neck fractures has continued to increase from an estimated 1.3 million hip fractures in 1990. This number is predicted to rise to 2.5 million by 2025 and 4.5 million by 2050, assuming there is no age specific increase. This number is mainly due to a larger proportion of the population surviving into their eighties. Taking the aging population into account, it has been estimated that there will be between 7.5 and 21.3 million hip fractures annually by 2050. Much of this increase will occur in Asia and developing countries. Patients who have presented with fracture neck of Femur over the age of 60, but have been performing from a functional point of view as a younger individual have been excellent candidates for Reduction with internal fixation¹. Several studies have suggested that reduction and fixation of an intracapsular fracture of the hip with multiple pins or screws is associated with a lower rate of morbidity and mortality than treatment with prosthetic replacement^{2,3}. The objective of the study was to evaluate the efficacy of internal fixation using cannulated cancellous screws in fracture neck of femur in patients aged above 50 years in terms of survival of the implants, complications, the survival of the patients, and the function of the patients in whom the fracture had healed without the development of osteonecrosis.

MATERIALS AND METHODS

We studied 30 cases of fracture neck of femur in patients above the age of 50 years presenting to emergency and out-patient department (OPD) within 10 to 30 days of injury which were treated by CANNULATED CANCELLOUS SCREWS, in the Department of Orthopaedics at R.L Jalappa Hospital, Kolar, between September 2010 to September 2012, selected on the basis of purposive sampling (Judgment sampling) method. Patients with pre-existing lesions of hip such as osteonecrosis of femoral head and degenerative arthritis, malignancy, neurological disorder like seizures, psychosis or mental deterioration and femoral neck fractures with severe posterior comminution were not selected in the study. At the end of 2 years following surgery one patient died and one patient was lost to follow up. There were 17 female (56%) patients and 13 male (34%) patients. The range of the age of patients of either sex was from 50 to 70 years. Detailed patient's notes were taken according to orthopaedic protocols. Patients were thoroughly assessed for any associated injury. Pre-operative radiographs were taken to access the fracture geometry in two planes. The fractures were classified accordingly with Garden's classification of fracture neck of femur. No attempt was made to access the viability of the femoral head by bone scanning or MRI studies. The patients were prepared and procedures were carried out in Spinal Anaesthesia. Fractures were managed by closed reduction and internal fixation performed with three cannulated screws in inverted triangle (FIGURE. 1).

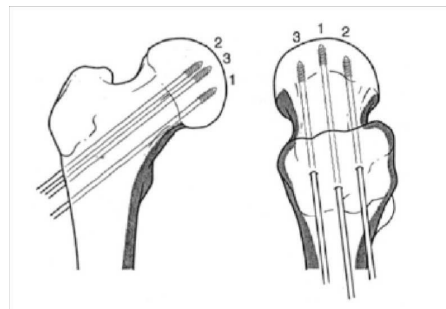


FIGURE 1
Steps of cannulated screw application

Post operatively, skin traction was applied to prevent rotation for one week. Procedure time was 30minutes on an average. The operated limb was protected for about6-8 weeks with non-weight bearing and patient was encouraged isometric exercise of thigh in bed. At six weeks, hip and knee range of motion was checked. Partial weight bearing

encouraged after six weeks which was increased gradually over a couple of months to full weight bearing. Maximum follow-up was 24 months duration. At each follow up, patients were evaluated according to Harris hip scoring system and radiographs were taken.

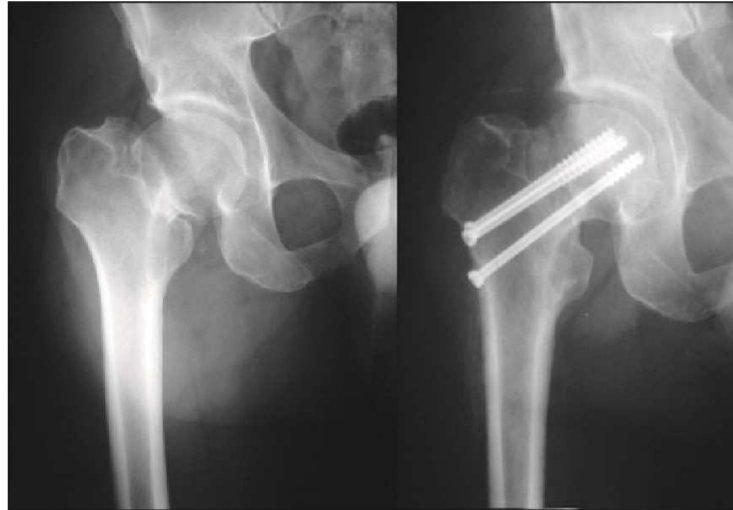


FIGURE 2
Pre-Operative and Post-operative Radiographs

RESULTS

Majority of fractures, 12(40%) were Garden type III. There were 11 (36.7%) patients with Garden type II fracture and 4 (13.3%) patients with Garden type I fracture. 3 (1%) patients had Garden type IV fracture.

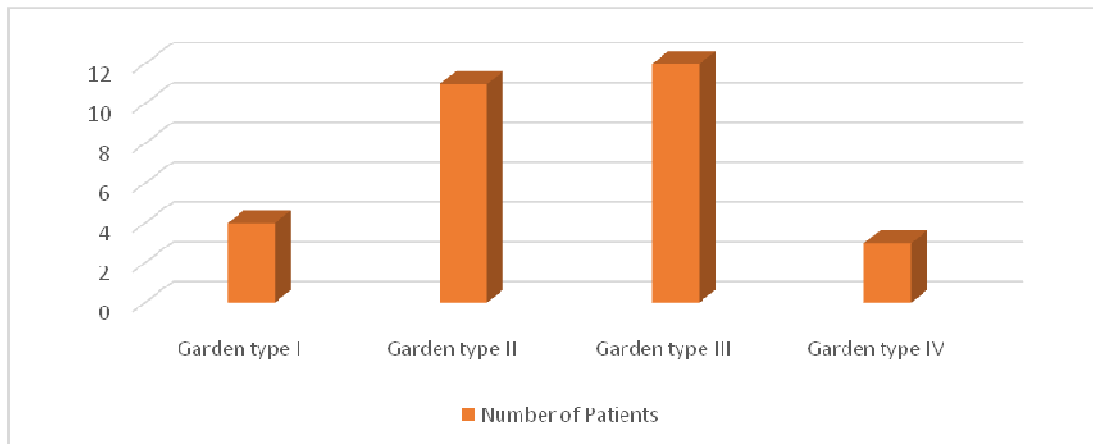


FIGURE 3
Type of Fractures

Thirteen patients were operated in the first week, 15 patients were operated in the second week and 2 patients were operated in the third week. Subtracting the 1 patient who was lost to follow-up and the 1 patient who died before union of the fracture could have

occurred, we have 28 patients who are available for complete analysis. Three (10%) patients had backing out of one of the screws, 1 (3.3%) had delayed union, and 1 (3.3%) had non-union.

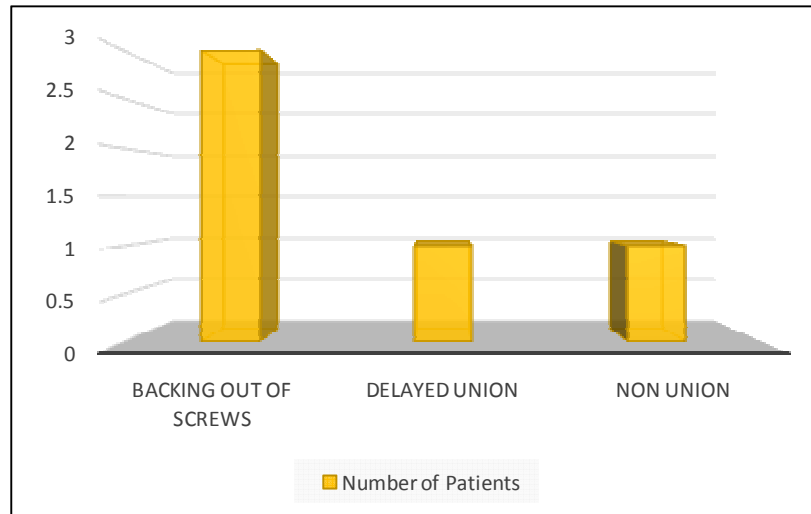


FIGURE 4
Complications

Functional results were assessed by using Harris hip scoring system. The Harris hip score at the end of six months ranged from 41.4 to 100. Six (21.4%) patients had hip scores from 90 to 100 (excellent). Seven (25%) had hip scores 80 to 89 (good). Eleven

hips (39.3%) were rated 70 to 79 (Fair) and four (14.3%) were rated less than 69 (poor). Thus 85.7% of the hips were classified as having a satisfactory to excellent result and 14.3% of the patients had a poor result.

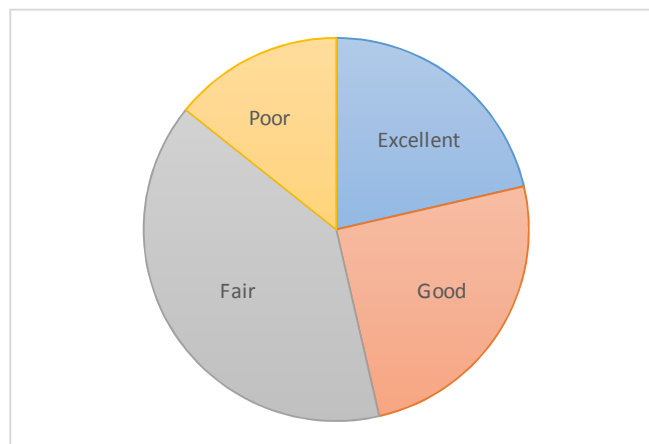


FIGURE 3
Pie-Chart showing the Results

DISCUSSION

Depending on the anteroposterior radiographic view available, they were grouped into Garden's classification. Majority (40%) of fractures were Garden type III on radiographic examination. There were 11 patients with Garden type II fracture and 4 patients with Garden type I fracture. 3 patients had Garden type IV fracture. We further grouped type III and type IV as displaced fractures which accounted for 50% of the fractures⁴. The complications following the internal fixation with cannulated cancellous screws for fracture neck of femur is reported in varying incidences. Phemister first reported an incidence of 10–20% in undisplaced fractures and 15 to 35% in displaced fracture. Ratliff reported an incidence of 42% (30 of 70 cases) while Allende-Lezama 25% (2 of 8 cases), Carrel and Carrel 35% (4 of 11 cases), Ingram and Bachinsky 55% (13 of 24 cases), McDougal 58% (14 of 24 cases)^{5, 6, 7}. In contrast to the above statistics we did not see any case of AVN. Revascularisation of the femoral head is a very slow process and the avascular changes can take place up to two years and sometimes beyond. Our study period of six months is not sufficient in regard to comment on the AVN. One patient in our study who was suffering from hypertension and aortic stenosis was lost in the follow up due to death; however the death was not directly related to the operative procedure and occurred three months postoperatively. Several studies have suggested that reduction and fixation of an intracapsular fracture of the hip with multiple pins or screws is associated with a lower rate of morbidity and mortality than treatment with prosthetic replacement.^{2,8, 9, 10, 11}. Lu-yao showed that the thirty day mortality rate was higher (10%) in Hemiarthroplasty as compared to 8% in internal fixation group¹². Holmberg⁸ et.al. Reported 5% incidence (134 of 2441 cases) at three months following internal fixation as compared with an incidence of 14% (13 of 95) in the Hemiarthroplasty group¹³. There was only one case (3.3%) of non-union reported in our series probably due to the improper positioning of the implant where the threads of one screw were crossing the fracture site. This incidence is much lower as compared to that reported in other series^{14, 15}. We observed that

5 patients (17.8%) in our series had no pain. Eight patients (28.6%) had slight pain and 14 (50%) patients had mild pain on ambulation requiring NSAIDs'. None of the patients had severe pain. All patients in the present study were elderly, and they seemed to be more sensitive to pain after surgery. Even though pain existed, it was hard for them or their families to consider undergoing a secondary operation to resolve this discomfort, most of which were tolerable with conservative management or simple analgesic use, and daily activities were not affected. Majority (71.4%) of the patients in our series had a slight limp. In 28.6% of patients limp was moderate. Limping is a common consequence of internal fixation. It is mainly due to the alteration in the abductor mechanism due to the impaction of neck on weight bearing. Exact cause cannot be attributed to this. Various criteria were used to assess the functional results following internal fixation. How best the patient could be returned to the premorbid functional status has been the main criteria. In India our customs demand squatting and sitting cross legged without difficulty. To achieve this patient should have a good range of flexion, abduction, adduction, and external rotation at the hip and full flexion at the knee. The distance patient could walk with or without support and the amount of movement at the hip are the major factors determining results in the western series whereas ability to squat and sit cross legged was principally emphasized by Indian series. The final results at 6 months after internal fixation with cannulated cancellous screws in our series were analysed by Harris hip scoring system³. The majority of our patients had good premorbid functional status: 97% were independent in their ADL, 3% (one case) were independent with assistive device. The primary aim of surgery was to return them to this high level of function. This objective was achieved with 78.6% of patients returning to their premorbid ambulatory status and 96.4% of patients having good pain relief at six months of follow up. Pain and limp form major criteria in Harris hip scoring system, thus bringing down the number of good and excellent results in our study. Since pain and limp were present in most of our cases, but none were severe enough to demand for any secondary surgical procedure.

CONCLUSION

Thirty cases of fracture neck of femur who were treated include Internal fixation using cannulated cancellous screws have been presented. The follow up results are analyzed and discussed. Most of the patients were in the age group of 50 - 70 years with the mean age of 58.77 years for males and 59.82 years for females. This is comparable to other series. Majority (40%) of fractures were Garden type III on radiographic examination. We excluded the patients who had communication of the posterior cortex of the neck. Majority (86.7%) of the patients had minimal trauma most of them slipped and fell down on flat ground or in bathrooms and were not able to walk or stand. Among the associated medical conditions, diabetes and gross anaemia were common. Patients were made to walk with partial weight bearing after six weeks. Most of the patients were discharged within two weeks of surgery. Of the 30 cases one patient died in our study who was suffering from hypertension and aortic stenosis however the death was not directly related to the operative procedure and occurred three months postoperatively. One patient was lost to follow up. Thus the remaining 28 patients were followed up for the assessment of their functional results. Complications following Internal fixations in our series are much less as compared to other

series. In our series, total Harris hip score at the end of six months ranged from 41.4 to 100. Majority, i.e., 85.7% of the hips were classified as having a satisfactory to excellent result and 14.3% of the patients had a poor result. We did not emphasised on exact parallel placement of screws in our study nor on the number of screws, inspite of this satisfactory results were seen in our study which is also supported by other studies. The success of Internal fixation nodoubt depends on preoperative planning and proper attention to surgical details to achieve the optimum biomechanical conditions. In conclusion, Osteosynthesis with cannulated screws fixation provides the patient a healed fracture with a living femoral head that is always better than areplacement; this can be achieved for a majority of patients with a procedure that is less invasive than arthroplasty. In patients who have treatment failure, total joint replacement or hemiarthroplasty can still be performed with results as good as or better than those of primary hemiarthroplasty. Internal fixation of femoral neck fractures is a good option in elderly patients. The mortality and morbidity rates are less compared to prosthetic replacement with high rates of union, operative procedure is simple, economical, complications are less disabling and early functional results are satisfactory.

REFERENCES

- Jarnlo GB, Thorngren KG. Background factors to hip fractures. *Clin Orthop Relat Res*, 287: 41-9, (1993)
- Holmberg S, Thorngren KG. Statistical analysis of femoral neck fractures based on 3053 cases. *Clin Orthop Relat Res*: 32-41 (1987).
- Elmerson S, Andersson CB, Pope MH, Zetterberg C. Stability of fixation in femoral neck fractures: Comparison of four fixation devices in vivo and in cadavers. *Acta Orthop Scand*, 8: 109-12, (1987).
- Parker MJ. Garden grading of intracapsular fractures: meaningful or misleading? *Injury*, 24: 241-2, (1993).
- Catto M. A histological study of avascular necrosis of the femoral head after transcervical fracture. *J Bone Joint Surg Br*, 47: 749-76, (1965).
- Steinberg ME, Hayken GD, Steinberg DR. A quantitative system for staging avascular necrosis. *J Bone Joint Surg Br*, 77: 34-41, (1995).
- Garden RS. Malreduction and avascular necrosis in subcapital fractures of the femur. *J Bone Joint Surg Br*, 53:183- 97, (1971).
- Holmberg S, Kalén R, Thorngren KG. Treatment and outcome of femoral neck fractures. An analysis of 2418 patients admitted from their own homes. *Clin Orthop Relat Res*, 218: 42-52, (1987).
- Eisler J, Cornwall R, Strauss E, Koval K, Siu A, Gilbert M. Outcomes of elderly patients with nondisplaced femoral neck

- fractures. Clin Orthop Relat Res, 399: 52-8, (2002).
10. Bosch U, Schreiber T, Krettek C. Reduction and fixation of displaced intracapsular fractures of the proximal femur. Clin Orthop Relat Res, 399: 59-71, (2002).
 11. Thorngren KG, Ceder L, Svensson K. Predicting results of rehabilitation after hip fracture. A ten-year follow-up study. Clin Orthop Relat Res, 287: 76-81 (1993).
 12. Lu-Yao GL, Keller RB, Littenberg B, Wennberg JE. Outcomes after displaced fractures of the femoral neck. A meta-analysis of one hundred and six published reports. J Bone Joint Surg Am, 76: 15-25, (1994).
 13. Zuckerman JD, Skovron ML, Koval KJ, Aharonoff G, Frankel VH. Postoperative complications and mortality associated with operative delay in older patients who have a fracture of the hip. J Bone Joint Surg A, 77: 1551-6, (1995).
 14. DeLee CJ. Fractures and dislocations of the hip. Fractures of the neck of the femur. In: Rockwood AC, Green PD, Bucholz WR, editors. Fractures in adults. 3th ed. Philadelphia: JB. Lippincott Company: 1481-538, (1991).
 15. Schmidt AH, Swiontkowski MF. Femoral neck fractures. OrthopClin North Am, 33: 97-111, (2002).