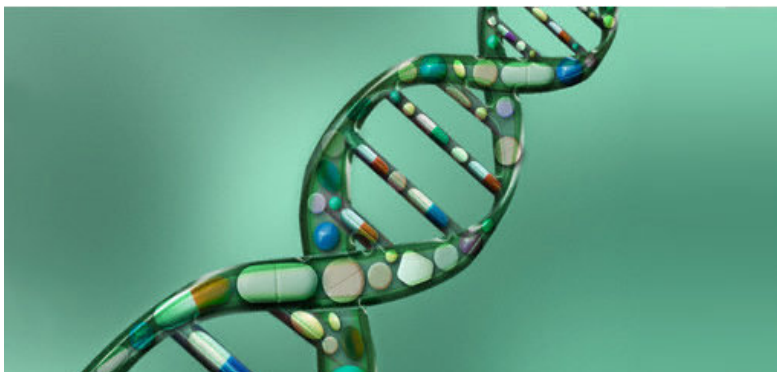



Internationally indexed journal

Indexed in Chemical Abstract Services (USA), Index coppernicus, Ulrichs Directory of Periodicals, Google scholar, CABI ,DOAJ , PSOAR, EBSCO , Open J gate , Proquest , SCOPUS , EMBASE ,etc.



Rapid and Easy Publishing

The "International Journal of Pharma and Bio Sciences" (IJPBS) is an international journal in English published quarterly. The aim of IJPBS is to publish peer reviewed research and review articles rapidly without delay in the developing field of pharmaceutical and biological sciences



Pharmaceutical Sciences

- Pharmaceutics
- Novel drug delivery system
- Nanotechnology
- Pharmacology
- Pharmacognosy
- Analytical chemistry
- Pharmacy practice
- Pharmacogenomics
- Polymer sciences
- Biomaterial sciences
- Medicinal chemistry
- Natural chemistry
- Biotechnology
- Pharmacoinformatics
- Biopharmaceutics



Biological Sciences

- Biochemistry
- Biotechnology
- Bioinformatics
- Cell biology
- Microbiology
- Molecular biology
- Neurobiology
- Cytology
- Pathology
- Immunobiology

Indexed in Elsevier Bibliographic Database
(Scopus and EMBASE)
SCImago Journal Rank 0.129
Impact factor 0.67*



*Instruction to Authors visit www.ijpbs.net

For any Queries, visit "contact" of www.ijpbs.net



A RARE CAUSE OF RETRO ORBITAL PAIN - CASE REPORT

DR. KUKU MARIAM SURESH^{*1}, DR. V. CHANDRASEKAR² AND DR. K. KANAKARAJ³

¹Post graduate, Department of Radiodiagnosis, Sree Balaji Medical College and Hospital, Chrompet, Chennai

²Professor, Department of Radiodiagnosis, Sree Balaji Medical College and Hospital, Chrompet, Chennai

³Assistant Professor, Department of Radiodiagnosis, Sree Balaji Medical College and Hospital, Chrompet, Chennai

ABSTRACT

Tolosa hunt Syndrome is known for its rarity. Patients complain of relapsing and remitting sharp retro orbital pain caused by non-granulomatous inflammation in the cavernous sinus. This 68 year old female patient presented with sharp retro orbital pain and frontal headache unresponsive to analgesics with mild ptosis and progressed to ipsilateral visual loss the following week. A known diabetic and hypertensive, she responded dramatically to oral corticosteroid therapy. Contrast MRI showed a homogenously enhancing mass in the left cavernous sinus which was isointense to gray matter on T2- weighted images. Brain MRI showed granulomatous inflammation in left cavernous sinus and thickening of the adjacent dura mater of the cranial base, suggesting the possibility of a coexisting focal hypertrophic cranial pachymeningitis. Steroid therapy with strict control of blood sugar is recommended in patients with THS complicated by diabetes. MRI is a valuable tool for serially monitoring the response of lesions to treatment in THS.

KEY WORDS: Granulomatous, Cavernous sinus, Ophthalmoplegia, Retro orbital



DR. KUKU MARIAM SURESH

Post graduate, Department of Radiodiagnosis, Sree Balaji Medical College and Hospital, Chrompet, Chennai

*Corresponding author

INTRODUCTION

Synonyms: superior orbital fissure syndrome, cavernous sinus syndrome, cavernous sinus granulomatosis and Tolosa-Hunt ophthalmoplegia. The Tolosa-Hunt syndrome is a rare syndrome with an annual incidence of approximately one case per million per year¹. This syndrome causes painful ophthalmoplegia with sharp retro orbital pain and is caused by an idiopathic granulomatous inflammation of the cavernous sinus. This syndrome was first described in 1954, and its dramatic response to glucocorticoid treatment was recognized a few years later²⁻⁴. Though considered a benign condition, permanent neurologic deficits may follow, and relapses are common. It is important to exclude all the malignant differentials before concluding Tolosa Hunt syndrome.

CASE REPORT

68 year old female presented with complaints of left orbital and retro orbital pain lasting for more than 6 weeks with associated giddiness, and hearing difficulty on both sides. Known type II diabetic and hypertensive on medication, she had undergone cataract correction 3 years back. Eye movements were intact with mild ptosis on the left. Fundoscopy with dilation showed features of diabetic neuropathy. Plain followed by contrast enhanced CT revealed an enhancing lesion filling the left cavernous sinus extending posteriorly along the left tentorium cerebelli towards the orbital apex. An incidental empty sella was identified. This was compared with the MRI findings which revealed an extra axial lesion appearing hypointense on T2 weighted images, in the left cavernous sinus extending posteriorly along the medial aspect of the left temporal lobe and left tentorium cerebelli and anteriorly towards the orbital apex. This lesion appears iso intense to muscle on T₁ weighted images. An attempted trans sphenoidal biopsy specimen revealed lymphocytic and plasma cell infiltration with few giant cell granulomas, and fibroblastic proliferation which helped in coming to a diagnosis of an idiopathic granulomatous inflammation in the left cavernous sinus. The

patient was treated with oral corticosteroids which gave almost complete relief of the partial ptosis and the sharp pain dramatically disappeared within a week after commencement of the treatment.

DISCUSSION

In 1961, this syndrome was initially described by E Tolosa in 1954⁵ and then by W. E Hunt et.al⁶ Incidence is found to be equally distributed among males and females. The age distribution is fairly uniform except for being rare before age 20 years old.

PATHOGENESIS

The Tolosa-Hunt syndrome is caused by an idiopathic inflammatory process. It is associated with signs of inflammation behind the eyes (cavernous sinus and superior orbital fissure). Histopathology of the biopsied specimen shows a nonspecific inflammation of the wall of the cavernous sinus, with a lymphocytic and plasma cell infiltration, giant cell granulomas, and fibroblasts proliferation^{2,3}. The inflammation causes pressure effect with secondary dysfunction of the structures within the cavernous sinus, including cranial nerves III, IV, and VI, as well as the superior divisions of cranial nerve V. Cases of Tolosa-Hunt syndrome have been reported in patients with other inflammatory disorders, such as systemic lupus erythematosus, but this may simply represent an association of the two autoimmune conditions⁷. The Headache Classification Subcommittee of the International Headache Society describes the course and features of Tolosa-Hunt syndrome as "episodic orbital pain associated with paralysis of one or more of the third, fourth, and/or sixth cranial nerves which usually resolves spontaneously but tends to relapse and remit"⁹

SIGNS AND SYMPTOMS

Symptoms are mostly unilateral and the patient complains of a sharp and intense pain behind

the eye not relieved with the common over-the-counter analgesics. The pain may be described as intense, severe, stabbing, boring or lancinating type of pain. Compression of the surrounding structures may cause other symptoms, namely, double vision, fever, chronic fatigue, vertigo or arthralgia. Occasionally the patient may present with a feeling of protrusion of one or both eyeballs (exophthalmos).^{3,4} Motor nerve dysfunction may manifest as diplopia, ptosis and pupillary dysfunction. Paralysis of various facial nerves and drooping of the upper eyelid (ptosis) is also an accompanying feature. Though THS is usually diagnosed by exclusion, the other tests include a variety of laboratory tests which help to rule out other causes of the patient's symptoms.⁵ These tests include a complete blood count, thyroid function tests and serum protein electrophoresis.⁵ Studies of cerebrospinal fluid may also be beneficial in distinguishing between THS and conditions with similar signs and symptoms.⁵

IMAGING

Imaging includes non-enhanced and enhanced computed tomography though conventional CT was found to be inconclusive, along with MRI.

CT

May show asymmetrical enlargement in the region of the cavernous sinus on the affected

side with or without contrast enhancement. Internal carotid artery narrowing, extension towards the superior orbital fissure and orbital apex comprise the secondary criteria.

MRI

Evidence of inflammatory changes may be seen in the region of the anterior cavernous sinus, superior orbital fissure with or without involvement of the orbital apex. Signal characteristics are generally non-specific but may include:

- T1 : involved region is iso intense 2 to hyper intense 8 compared with muscle
- T2 : involved region is hyper intense
- C+ (Gd) : may show homogenous enhancement during active phase with a resolution of enhancement following treatment with corticosteroids^{6,10}

In 1961, Hunt et al outlined six clinical criteria characterizing the syndrome: (1) steady, gnawing, retro orbital pain; (2) defects in the third, fourth, sixth, or the first branch of the fifth cranial nerve, with less common involvement of the optic nerve or sympathetic fibers around the cavernous carotid artery; (3) symptoms lasting days to weeks; (4) occasional spontaneous remission; (5) recurrent attacks; and (6) prompt response to steroid therapy.

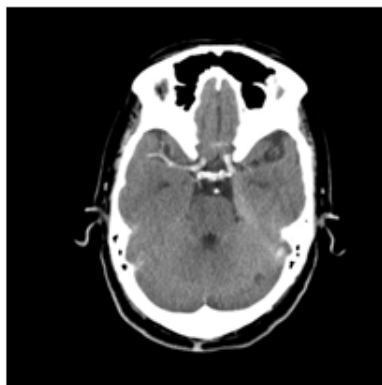

Figure 1

An axial section of CECT showing a homogeneously enhancing filling the left cavernous sinus and extending posteriorly along medial aspect of left temporal lobe & the left tentorium cerebelli and anteriorly extending towards the left orbital apex

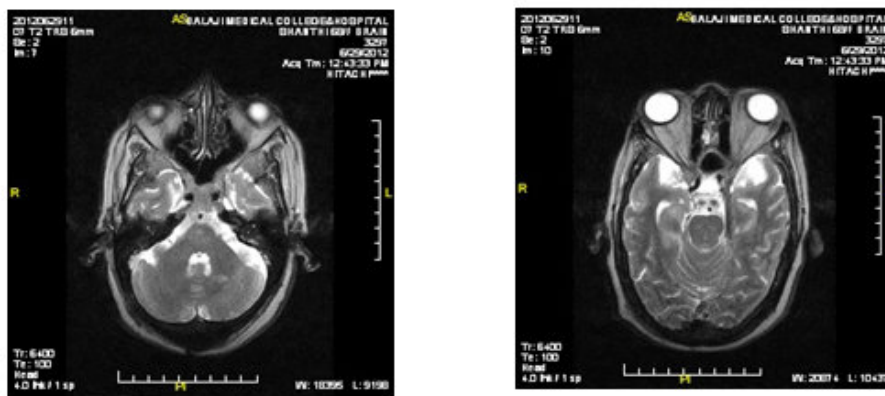


Figure 2
Axial sections of T₂ weighted MRI shows extra axial hypointense lesion in the left cavernous sinus extending posteriorly along the medial aspect of the left temporal lobe and left tentorium cerebelli.

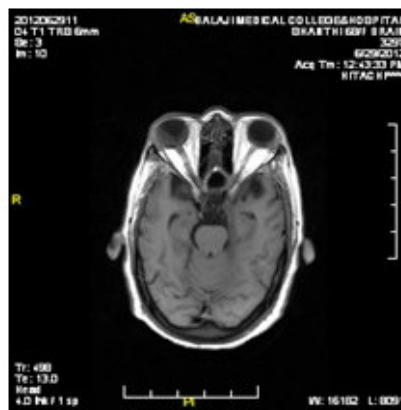


Figure 3
Same lesion as in figure 2 appears iso intense to muscle on T1 weighted images.

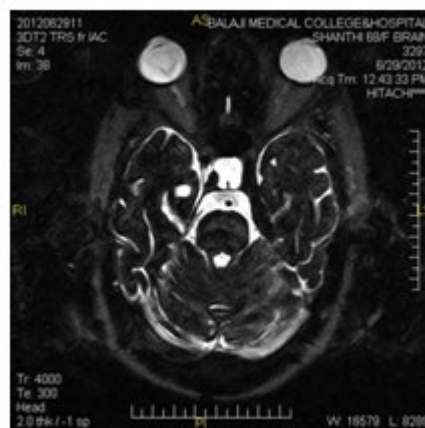


Figure 4
3D IAC images showing a focal lesion filling the left cavernous sinus extending posteriorly along the left tentorium cerebelli towards the supra orbital fissure. No significant IAC occlusion identified in this case.

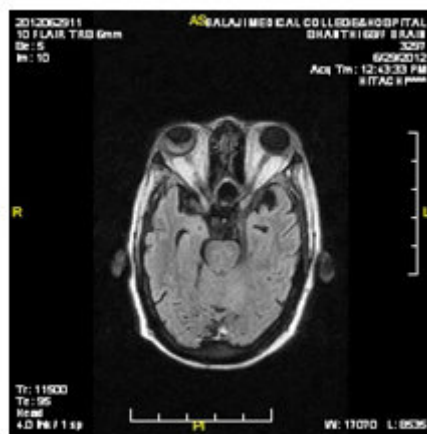


Figure 5
Axial FLAIR section shows a hypointense lesion in the left cavernous sinus with no associated edematous changes.

CONCLUSION

This rare case of Tolosa Hunt Syndrome showed dramatic relief with oral corticosteroids and was followed up with biopsy and repeat MRI of the brain which showed almost complete reversal of the findings in the left cavernous sinus. The symptoms were relieved starting from the third day after initiating the corticosteroid therapy and the patient showed dramatic improvement with no relapse in the following 12 months. Numerous reports have

confirmed these findings in history. The clinical syndrome has been found in virtually every continent of the world¹¹⁻¹⁸. The non-specific nature of the pathological process has been confirmed,^{6,12,14} as has the dramatic clinical response to systemic corticosteroids.^{12,17,21} Corticosteroid therapy is generally safe and can achieve satisfactory response and perhaps better fetal outcome²²

REFERENCES

1. Iaconetta G, Stella L, Esposito M, Cappabianca P. Tolosa-Hunt syndrome extending in the cerebello-pontine angle. *Cephalalgia* 2005; 25:746.
2. TOLOSA E. Periarteritic lesions of the carotid siphon with the clinical features of a carotid infraclinoidal aneurysm. *J Neurol Neurosurg Psychiatry* 1954; 17:300.
3. HUNT WE, MEAGHER JN, LEFEVER HE, ZEMAN W. Painful ophthalmoplegia. Its relation to indolent inflammation of the cavernous sinus. *Neurology* 1961; 11:56.
4. Smith JL, Taxdal DS. Painful ophthalmoplegia. The Tolosa-Hunt syndrome. *Am J Ophthalmol* 1966; 61:1466.
5. Danette C Taylor, DO. "Tolosa-Hunt syndrome". eMedicine. Retrieved 2008-01-21.
6. Tolosa E. Periarteritic lesions of the carotid siphon with the clinical features of a carotid infraclinoidal aneurysm. *J. Neurol. Neurosurg. Psychiatr.* 1954;17 (4): 300-2.doi:10.1136/jnnp.17.4.300 - Free text at pubmed - Pubmed citation
7. Hunt WE, Meagher JN, Lefever HE et-al. Painful ophthalmoplegia. Its relation to indolent inflammation of the cavernous sinus. *Neurology.* 1961;11 : 56-62.
8. Calistri V, Mostardini C, Pantano P, et al. Tolosa-Hunt syndrome in a patient with

- systemic lupus erythematosus. *Eur Radiol* 2002; 12:341.
9. Headache Classification Subcommittee of the International Headache Society. The international classification of headache disorders, 2nd edition. *Cephalalgia* 2004; 24 Suppl 1:8.
 10. *Journal of Roentgenology* 195:3_supplement, S38-S41.
 11. Lakke JPWF (1962) Superior orbital fissure syndrome. Report of a case caused by local pachymeningitis. *Arch Neurol* 7:289–300.
 12. Mathew NT, Chandy J (1970) Painful ophthalmoplegia. *J Neurol Sci* 11:243–256.
 13. Smith JL, Schatz NJ, Farmer P (1972) Tolosa-Hunt syndrome: the pathology of painful ophthalmoplegia. in *Neuro-ophthalmology. Symposium of the University of Miami and the Bascom Palmer Eye Institute. Vol VI.* ed Smith JL (Mosby, St Louis)
 14. Spinnler H (1973) Painful ophthalmoplegia; the Tolosa-Hunt syndrome. *Med J Aust* 2:645–646.
 15. Roca PD (1975) Painful ophthalmoplegia: the Tolosa-Hunt syndrome. *Ann Ophthalmol* 7:828–834
 16. Cohn DF, Carasso R, Streifler M (1979) Painful ophthalmoplegia. *Eur Neurol* 18:373–381
 17. Muhletaler CA, Gerlock AJ (1979) Orbital venography in painful ophthalmoplegia (Tolosa-Hunt syndrome). *Am J Radiol* 133:31–34.
 18. Inzafari D, Sita D, Marconi GP et al. (1981) The Tolosa-Hunt syndrome: further clinical and pathogenetic considerations based on the study of eight cases. *J Neurol* 224:221–228
 19. Aron-Rosa D, Doyon D, Sallamon G et al. (1978) Tolosa-Hunt syndrome. *Ann Ophthalmol* 10:1161–1168.
 20. Goadsby PJ, Lance JW (1989) Clinicopathological correlation in a case of painful ophthalmoplegia: Tolosa-Hunt syndrome. *J Neurol Neurosurg Psychiatry* 52:1290–1293.
 21. Hunt WE (1976) Tolosa-Hunt syndrome: one cause of painful ophthalmoplegia. *J Neurosurg* 44:544–549.
 22. *Int J Pharm Bio Sci* 2013 Oct; 4(4): (B) 694 - 697