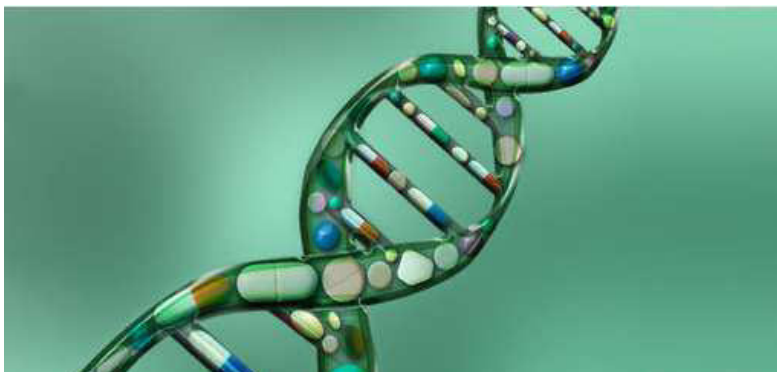



## *Internationally indexed journal*

Indexed in Chemical Abstract Services (USA), Index coppernicus, Ulrichs Directory of Periodicals, Google scholar, CABI ,DOAJ , PSOAR, EBSCO , Open J gate , Proquest , SCOPUS , EMBASE ,etc.



### *Rapid and Easy Publishing*

*The "International Journal of Pharma and Bio Sciences" (IJPBS) is an international journal in English published quarterly. The aim of IJPBS is to publish peer reviewed research and review articles rapidly without delay in the developing field of pharmaceutical and biological sciences*



#### **Pharmaceutical Sciences**

- Pharmaceutics
- Novel drug delivery system
- Nanotechnology
- Pharmacology
- Pharmacognosy
- Analytical chemistry
- Pharmacy practice
- Pharmacogenomics
- Polymer sciences
- Biomaterial sciences
- Medicinal chemistry
- Natural chemistry
- Biotechnology
- Pharmaco-informatics
- Biopharmaceutics



#### **Biological Sciences**

- Biochemistry
- Biotechnology
- Bioinformatics
- Cell biology
- Microbiology
- Molecular biology
- Neurobiology
- Cytology
- Pathology
- Immunobiology

Indexed in Elsevier Bibliographic Database  
(Scopus and EMBASE)  
SCImago Journal Rank 0.129  
Impact factor 0.47\*



\*Instruction to Authors visit [www.ijpbs.net](http://www.ijpbs.net)

For any Queries, visit "contact" of [www.ijpbs.net](http://www.ijpbs.net)



## COMPARATIVE RESULTS OF ENDOSCOPIC VERSUS EXTERNAL DACRYOCYSTORHINOSTOMY FOR ACQUIRED NASO-LACRIMAL DUCT OBSTRUCTION

DR SHIV KUMAR RAGHUWANSHI\*<sup>1</sup> M.S. AND DR SAPNA RAGHUWANSHI<sup>2</sup> M.S.

<sup>\*1</sup> Assistant Professor, Department of ENT, LN Medical College and research centre, Bhopal

<sup>2</sup> Consultant Ophthalmologist, Bhopal, M.P.

### ABSTRACT

**Introduction:** Dacryocystorhinostomy (DCR) is the treatment of choice for acquired nasolacrimal duct obstruction, commonly caused by chronic dacryocystitis. Although external DCR is traditionally regarded as gold standard, endoscopic DCR is evolving as an equally effective alternative nowadays, with added advantage of preserving the lacrimal pump system and leaving no surgical scar.

**Purpose:** To compare the success rates of external and internal approaches of DCR for acquired nasolacrimal duct obstruction.

**Study design:** A prospective, open label, non-randomized cohort study.

**Method:** Ninety consecutive patients with acquired nasolacrimal duct obstruction (62 females, 18 males, mean age 62.5 years) underwent DCR surgery. 60 patients were selected for endoscopic endonasal DCR, while the remaining 30 underwent DCR via external route. Success rate was defined by resolution of symptoms with patency of lacrimal drainage system immediately after surgery and at follow ups.

**Results:** The overall immediate success rate (achievement of patency by irrigation) was 90% (81/ 90 cases). Results were slightly better in endonasal DCR group (56 / 60; 93.33%) as compared to the external DCR (25/30; 83.33%), although statistically insignificant (p= 0.856). Long-term symptom relief and anatomical patency (6–12 months postoperatively) was retained in 53 (88.33%) patients of endonasal DCR and in 23 (76.66%) patients of external DCR. Out of 14 failed cases, anatomical obstruction at the fistula site was found in 9 (64.28%) case, the rest had functional failure.

**Conclusion:** The success rate of DCR in our group of patients was high with an overall few complications. The results of endoscopic DCR were comparable to that of external DCR.

**KEYWORDS:** Nasolacrimal duct obstruction, Irrigation, Epiphora, Endoscopic surgery, Dacryocystorhinostomy.



**DR SHIV KUMAR RAGHUWANSHI**

Assistant Professor, Department of ENT, LN Medical College and research centre, Bhopal

\*Corresponding author

## INTRODUCTION

Dacryocystorhinostomy (DCR) has been the standard treatment for acquired nasolacrimal duct obstruction. External DCR was first described by Toti<sup>1</sup> (1904) and was later modified by the addition of suturing of the mucosal flaps<sup>2</sup>, thus forming an epithelium-lined fistula. Several case series have estimated the success rate of external DCR to be between 85% and 95%<sup>3-5</sup>. The endonasal approach was introduced in 1893 by Caldwell<sup>6</sup> and modified by West<sup>7</sup> in 1910 and Halle<sup>8</sup> in 1914. The approach failed to gain popularity due to poor access to the nasal cavity. With the advent of the nasal endoscope and functional endoscopic sinus surgery<sup>9</sup> in the early 1990s, there was renewed interest in endonasal DCR. McDonogh et al introduced endonasal DCR in its present form in 1989<sup>10</sup>. The reported success rate for endonasal DCR ranges from 63% to 90%<sup>11</sup>. However, monitoring the success of DCR is difficult due to lack of standardization of outcome. Few investigators advocate monitoring the rhinostomy using postoperative endoscopy<sup>12</sup>. Dye application to the conjunctival fornix during endoscopy and the visualization of the dye at the osteotomy (functional endoscopic dye test) site has been shown to be useful in assessing rhinostomy patency<sup>13</sup>. The present study aimed to compare success rates of DCR surgery performed by external versus endoscopic routes and to appraise the results for anatomical as well as functional patency.

## MATERIALS AND METHODS

We performed a clinical prospective study of 90 patients with diagnosis of nasolacrimal duct obstruction admitted at JKHMRC & LN Medical college, Bhopal, India from October 2008 to April 2011. All patients underwent a comprehensive ENT and ophthalmic examination along with irrigation of the nasolacrimal drainage system and an intranasal examination. Patients were excluded if tearing was due to canalicular obstruction or lower eyelid malposition. Selection of the type of surgery was left to patient choice. All patients had preoperative counselling and both procedures were

explained in detail with their advantage and disadvantages.

**Failure was defined as any of the following:**

- (1) No improvement in tearing symptoms or any episode of post-operative dacryocystitis.
- (2) Inability to irrigate the lacrimal system postoperatively.

Success was defined as marked improvement in tearing—i.e, patients did not report additional episodes of tearing and patency of lacrimal drainage system postoperatively was normal. Postoperative nasal endoscopy was performed in all failed cases. Patients with scar formation at the osteotomy site were planned for surgical endoscopic revision in the operating theatre. No revision case had to be included in this study. A silicone stent was replaced at the time of surgical revision.

### **Surgical Procedure**

#### **A. External DCR**

Surgery was performed under local anesthesia and if required, sedation was also given. Incision was taken over anterior lacrimal crest. Medial palpebral ligament was identified and orbicularis oculi was separated. Reflection of periosteum and dissection of lacrimal sac from lacrimal fossa was done. Sac was excised to make 'H' shaped anterior and posterior flaps. Bony osteum of sufficient size was made with bone punch. Nasal mucosa was cut to make anterior and posterior flaps. Subsequently anterior to anterior and posterior to posterior flaps were sutured with 2 to 3 interrupted sutures by 6-0 vicryl.

#### **B. Endonasal DCR**

Surgery was performed preferably done under local anesthesia. In children and uncooperative patients general anesthesia was used. Nasal cavity was packed with gauze soaked in 4% xylocaine with 1:100,000 adrenaline, 15 minutes before the procedure. The mucosa anterior to uncinat process was infiltrated with 2% xylocain with 1:100000 adrenaline. A 30<sup>0</sup> rigid endoscope was used. Using the sickle knife with cautry Sickle knife

with cautery was used to incise and remove a rectangular 5 mm X 10 mm portion of mucosa anterior to upper half of the uncinat process. Lacrimal bone and maxillary frontal process were identified and nibbled away by a 2 mm Kerrison punch. Lacrimal sac was exposed by further removal of the bone. The medial wall of sac was tented by lacrimal probing. The sac was then slit open with keratome. The medial wall of sac was then removed with endoscopic DCR scissor Syringing was done with saline and methylene blue to confirm the free flow and patency. No stent was inserted in any in this study. As post-operative medication, nasal decongestants and saline douching of the nasal cavity was done. Nasal saline sprays were given for 6 weeks to reduce crusting inside the nose. The patients were asked to report after at 2 weeks for endoscopic removal of crusts around the lacrimal window. All patients of both the groups were followed once a week for 4 weeks and then after 3 months, 6 months and 1 year.

## RESULTS

A total of 90 patients (62 females, 18 males, mean age 62.5 years) underwent DCR surgery. (Figure 1) Post-operatively, the patency demonstration by irrigation was achieved in 81 cases (90%) {out of them 56 / 60 (93.33%) in the endonasal DCR group and 25 / 30 (83.33%) in external DCR group}. (Table I) However, the difference between the two sub-groups was not found to be statistically significant as tested by chi-square test ( $p>0.05$ ). The immediate post-operative failure (inability to achieve anatomical patency) was noted in 9 cases (10%) [4 cases in endonasal group and 5 in external group]. The long-term patency and symptom relief (12 months postoperatively) was achieved in 76 patients, [out of them 53 (88.33%) of 60 patients in the endonasal DCR group and 23 (76.66%) of 30 patients in the external DCR group]. Again, the difference between the two sub-groups was not statistically significant ( $p>0.05$ ). At the end of the follow-up period, a total of 14 failures were observed including anatomical obstruction at the fistula site in 9 (64.28% of failed case) and physiological malfunction in 5(35.71% of failed cases). [7

cases in each endoscopic or external DCR groups].

The operation was classified as successful by the objective demonstration of a patent nasolacrimal system through irrigation and improvement of symptoms (tearing). This was found in 76 patients (84.44%) and failures in 14 patients (15.55%). Demonstration of patency by irrigation was achieved in 81 case (90%) and failure in 9 case (10%). 56 (93.33%) of 60 patients for the endonasal DCR and 25 (83.33%) of 30 patients for external DCR surgery {anatomical patency and symptom relief (6–12 months postoperatively) was achieved in 53 (53/60%) of 60 patients in the endonasal DCR group and 23 (23/30%) of 30 patients in the external DCR group} (Table I). The complication incidence was low and similar in both operations. Three patients had postoperative haemorrhage (one who had endonasal DCR surgery and two having external DCR surgery). Postoperative haemorrhage was either wound haemorrhage or epistaxis. All of these patients were treated conservatively, including nasal spray and/or packing. Haemostasis was achieved with no secondary haemorrhage resulting from surgical interventions. One patient of external DCR group had hypertrophied external scar. Two patients of endonasal DCR group had nasal synechia formations which were removed successfully as OPD procedure. Two patients had formation of granulation at the ostium with narrowing in the endonasal group. There were no documented orbital and subcutaneous emphysema, conjunctival fistula formation, retrobulbar hemorrhage, medial rectus paresis, or orbital fat herniation. Five (8.33%) patient out of 60 (endoscopic group) required additional surgery (2 patients required septoplasty, 2 patients needed unsectomy 1 patient underwent removal of chonca bullosa concomitantly with endonasal DCR surgery) (Table II)

## DISCUSSION

Advantages of endoscopic DCR over the traditional external approach include avoidance of skin incision along with its possible complications; preservation of the

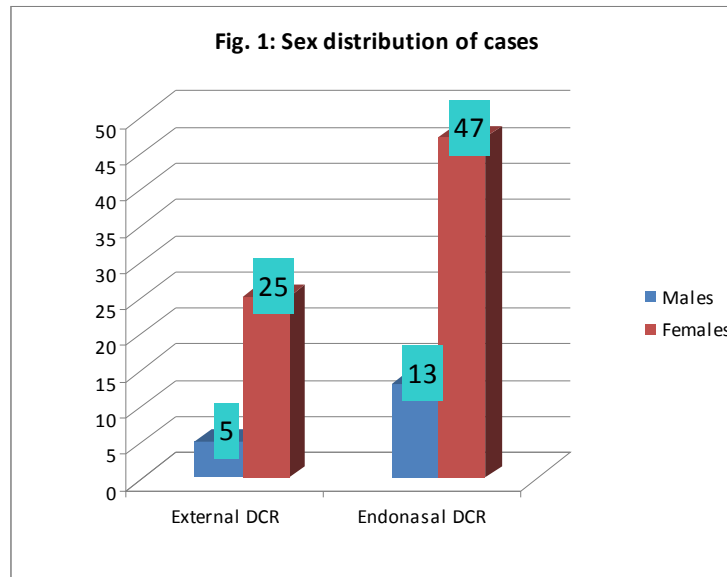
pump mechanism of the orbicularis oculi muscle, less bleeding and the ability to address nasal or paranasal sinus abnormality at the same time. Limitation of injury to tissues at the osteotomy site, and faster rehabilitation are also noted. Drawbacks include longer operative time, technical difficulties, and specific instrumentation<sup>10, 13, 14</sup>. However, some investigators have found similar or even shorter operative times in endoscopic DCR in comparison to external DCR<sup>15, 16</sup>. External DCR is technically easier, with an unimpaird view of the surgical area and well-defined landmarks allowing the creation of a wide bony window and the use of mucosal flaps to obtain an epithelialized DCR tract<sup>15</sup>. It also enables lacrimal sac biopsy in cases of an abnormally appearing sac during surgery; this may be somewhat difficult using the endoscopic or endonasal approach, which is contraindicated in patients in whom there is suspicion of lacrimal system neoplasia<sup>17</sup>, although with good instrumentation and surgical technique, a good biopsy of the lacrimal sac can be obtained via endonasal route. Published results for successful endonasal endoscopic DCR range from 63% to 99%<sup>13, 15, 18</sup> with endosurgical DCR being more successful than endolaser DCR<sup>13</sup>. Despite a general belief that external DCR is more successful than endonasal DCR, some authors conclude that it is difficult to make a definite evidence-based determination about the relative efficacies of endonasal and external DCR because of deficiencies in the reported literature<sup>14</sup>. A learning curve of the endoscopic procedure has also been demonstrated in several studies, with higher success in more experienced surgeons<sup>19</sup>. In the present study, the immediate success rate was 90% as demonstrated by post-operative patency demonstration by irrigation. Both endonasal (93.33%) and external (83.33%) DCR operations were highly successful in our series. These rates could have been actually even higher if we take only anatomical patency as the endpoint of the surgical outcome. A long follow-up period in our study could also have possibly reduced the visible results. (Table III) Most studies, including ours, are not controlled for size of the anatomic tissue being removed or for the site

of obstruction. Several studies showed that success rates of endoscopic or external DCR were significantly higher for common canalicular and lacrimal sac/duct obstruction than for canalicular obstruction, with a complete cure achieved in the latter in only 47% to 54%<sup>20, 21</sup>. The definition of success or end point may also differ, with the likelihood of lower success when subjective symptoms are taken into consideration<sup>22</sup>. Success depends upon creating a wide osteotomy and preservation of mucosa around the lacrimal window to reduce the chance of postoperative scarring and stenosis<sup>20</sup>. Longer follow-up may be associated with decreased success rates although this finding is questioned in other reports<sup>21, 23</sup>. Revision of DCR can be performed successfully via an endoscopic approach and usually requires scar excision at the osteotomy site and re-intubation of the lacrimal system using a silicone stent. Reported success rates of endoscopic revision range from 70% to 90% using a single revision<sup>20</sup> no revision case was needed in our study.

As many as 25% of patients may have concomitant nasal or sinus pathology such as septal deviation or nasal polyps, which can be addressed simultaneously at the time of endonasal surgery without affecting the functional outcome<sup>24</sup>. Removal of concha bullosa and uncinectomy have also been performed concomitantly with endonasal DCR; surgery should be customized to the individual nasal anatomy<sup>24</sup>. We also performed septoplasty in two patients, uncinectomy in two cases and removal of concha bullosa in one patient simultaneously with endoscopic DCR. Potential complications of external DCR include bruising, wound infection, cerebrospinal fluid leaking, punctal eversion, inadvertent incision of periorbita; endonasal DCR complications include damage to the nasal mucosa with scar formation, perirhinostomy granuloma, orbital fat prolapse, transient damage to the medial rectus muscle with diplopia, secondary canalicular stenosis, canalicular cheese-wiring by the silicone stent, sump syndrome, recurrence of lacrimal mucocele, and adhesions between the ostium and the septum<sup>13, 15, 25</sup>. Most complications for both

external and internal DCRs are extremely rare. We encountered only few complications during operation as well as during the follow ups. Mild post-operative hemorrhage, nasal synechia and granulation tissue formation were the only and easily handled complications in our patients. It could be

suggested that both the endoscopic and external DCR operations may be nearly equally successful in cases of acquired nasolacrimal obstruction due to chronic dacryocystitis and the patient preference and availability of each service should direct management in individual cases.



**Table I**  
**Summary of surgery success**

Surgical result	Endonasal DCR	External DCR	Chi-square test	P value
Anatomical patency	56/60(93.33%)	25/30(83.33%)	0.033	0.856
Anatomical patency and symptom relief	53/60(88.33%)	23/30(76.66 )	0.065	0.798

*(Statistical difference between the two groups considered non-significant as p > 0.05)*

**Table II**  
**showing complications**

S N	Complication	Endonasal DCR	External DCR
1.	Haemorrhage	1	2
2.	Nasal Synechia formation	2	-
3.	Granulomatous at ostium	2	-
4.	External hypertrophied scar	-	1

**Table III**  
**Comparison of success rate of external and endoscopic DCR with previous studies**

Investigator	Number of cases		Success rate	
	Endonasal DCR	External DCR	Endonasal DCR	External DCR
1 Ben simon GJ et al [11]	86	90	83.7%	70.0%
2 Karim R et al [26]	102	98	82.3%	81.6%
3 Khan MKH [27]	15	15	73.3%	80%
4 Tsirbas et al [28]	31	24	94%	96%
5 Present study	60	30	88.3%	77.7%

## CONCLUSION

DCR is the treatment of choice for the treatment of nasolacrimal duct obstruction. Overall, both the external and endoscopic approaches have showed comparable results and low complication rates in the literature. The basic advantage in endoscopic route is avoidance of scar and a disturbed lacrimal pump mechanism. However, this method is also more demanding in terms of meticulous

anatomical acquaintance of the operating surgeon and proper training in endoscopic surgery. These aspects may be important deciding factors during selection of the type of operation. The patients must also be thoroughly explained the benefits and challenges of all the possible options before the surgery.

## REFERENCES

1. Toti A (1904) Nuovo metodo conservatore di cura radicale delle suppurazioni croniche del sacco lacrimale (Dacriocistorinostomia). *Clin Mod Firenze* 10: 385–7
2. Dupuy- Dutemps L, Bourguet J (1921) Procède plastique de dacryocystorhinostomie et ses resultants. *Ann Oculist* 158: 241–61
3. Becker BB (1988) Dacryocystorhinostomy without flaps. *Ophthalmic Surgery* 19: 419–27
4. Cokkeser Y, Evereklioglu C, Er H (2000) Comparative external versus endoscopic dacryocystorhinostomy: Results in 115 patients (130 eyes). *Otolaryngology - Head & Neck Surgery* 123: 488–91
5. Emmerich KH, Busse H, Meyer-Rusenber HW (1994) Dacryocystorhinostomia externa. Technique, indications and results. *Ophthalmologie* 91: 395–8
6. Caldwell GW (1893) Two new operations for obstruction of the Nasal duct. *New York Medical Journal* 57: 581-582
7. West JM (1910) A window resection of the nasal duct in cases of stenosis. *Transactions of the American Ophthalmological Society* 12(Pt 2): 654–8
8. Halle M. (1914) Zur intranasalen operation am tranensack. *Arch Laryngol Rhinol* 28: 256–66
9. Kennedy DW (1985) Functional endoscopic sinus surgery technique. *Archives of Otolaryngology - Head & Neck Surgery* 111: 643–9
10. McDonogh M, Meiring JH (1989) Endoscopic transnasal dacryocystorhinostomy. *Journal of Laryngology and Otology* 103: 585–7
11. Ben Simon GJ, Joseph J, Lee S, Schwarcz RM, McCann JD, Goldberg RA (2005) External versus endoscopic dacryocystorhinostomy for acquired nasolacrimal duct obstruction in a tertiary referral centre. *Ophthalmology* 112: 1464–8
12. Olver J, Minasian M (1998) Nasal endoscopy for ophthalmologists. *CME J Ophthalmol* 2: 73–7
13. Moore WMH, Bentley CR, Olver JM (2002) Functional and anatomic results after two types of endoscopic endonasal dacryocystorhinostomy: surgical and holmium laser. *Ophthalmology* 109: 1575–82
14. Woog J, Kennedy RH, Custer PL, et al (2001) Endonasal dacryocystorhinostomy. A report by the American Academy of Ophthalmology. *Ophthalmology* 108: 2369 –77
15. Dolman PJ (2003) Comparison of external dacryocystorhinostomy with non-laser endonasal dacryocystorhinostomy. *Ophthalmology* 110: 78-84
16. Malhotra R, Wright M, Olver JM (2003) A Consideration of the time taken to do dacryocystorhinostomy (DCR) surgery. *Eye* 17: 691-696
17. Durvasula V, Gatland DJ (2004) Endoscopic dacryocystorhinostomy: long-term results and evolution of

- surgical technique. *J Laryngol Otol* 118: 628–32
18. Weidenbecher M, Hosemann W, Buhr W (1994) Endoscopic endonasal dacryocystorhinostomy: results in 56 patients. *Ann Otol Rhinol Laryngol* 103: 363–7
  19. Camara JG, Santiago MD (1999) Success rate of endoscopic laser assisted dacryocystorhinostomy. *Ophthalmology* 106: 441–2
  20. Yung MW, Hardman-Lea S (2002) Analysis of the results of surgical endoscopic dacryocystorhinostomy: effect of the level of obstruction. *Br J Ophthalmol* 86: 792–4
  21. Delaney YM, Khooshabeh R (2002) External dacryocystorhinostomy for the treatment of acquired partial nasolacrimal obstruction in adults. *Br J Ophthalmol* 86: 533–5
  22. Goldberg RA (2004) Endonasal dacryocystorhinostomy: is it really less successful? *Arch Ophthalmol* 122: 108–10
  23. Mantynen J, Yoshitsugu M, Rautiainen M (1997) Results of dacryocystorhinostomy in 96 patients. *Acta Otolaryngol Suppl* 529: 187–9
  24. Fayet B, Racy E, Assouline M (2002) Systematic unciformectomy for a standardized endonasal dacryocystorhinostomy. *Ophthalmology* 109: 530–6
  25. Fayet B, Racy E, Assouline M (2004) Complications of standardized endonasal dacryocystorhinostomy with unciformectomy. *Ophthalmology* 111: 837–45
  26. Karim R, Ghabrial R, Lynch TF, Tang B (2011) A comparison of external and endoscopic endonasal dacryocystorhinostomy for acquired nasolacrimal duct obstruction. *Clin Ophthalmology* 5: 979–989
  27. Khan MKH, Hossain MA, Hossain MJ, Al-Masud A, Rahman MZ (2011) Comparative study of external and endoscopic endonasal dacryocystorhinostomy for the treatment of chronic dacryocystitis. *JAFMC Bangladesh* 7: 15–17
  28. Tsirbas A, Davis G, Wormld PJ (2004) Mechanical endonasal dacryocystorhinostomy versus external dacryocystorhinostomy. *Ophthal Plast Reconstr Surg* 20: 50–56.