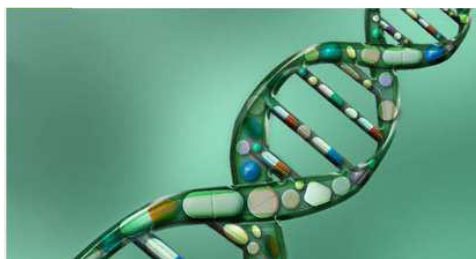



INTERNATIONAL JOURNAL
OF PHARMA AND BIO SCIENCES

Internationally Indexed Journal

Indexed in Chemical Abstract Services(USA),Index Copernicus ,Ulrichs Directory of Periodicals,Google scholar ,Cabi ,DOAJ ,PSOAR, EBSCO ,SCOPUS, EMBASE etc.



Rapid Publishing

The International Journal of Pharma and Bio Sciences (IJPBS) is an international journal published quarterly. The Aim of IJPBS is to publish peer reviewed research and review articles in less time without much delay in the developing field of Pharmaceutical and Biological sciences. One week from the date of manuscript submission author gets the decision of acceptance and if accepted the manuscript will be processed within 3 weeks (approx.) for publication.

Pharmaceutical Sciences

Branches

- Pharmaceutics
- Novel drug delivery sys
- Nanotechnology
- Pharmacology
- Pharmacognosy
- Analytical chemistry
- Pharmacy practice
- Pharmacogenomics
- Polymer sciences
- Biomaterial sciences
- Medicinal chemistry
- Natural chemistry
- Biotechnology
- Pharmacoinformatics
- Biopharmaceutics

Biological Sciences

Branches

- Biochemistry
- Biotechnology
- Bioinformatics
- Cell biology
- Microbiology
- Allied Sciences
- Molecular biology
- Neurobiology
- Cytology
- Pathology
- Immunobiology



Impact Factor 0.47*

**Refer Instruction to authors available at www.ijpbs.net*



Indexed In Elsevier Bibliographic Database
(SCOPUS, EMBASE and Sciverse)

Journal Home page
www.ijpbs.net

FOR INSTRUCTION TO AUTHORS VISIT
www.ijpbs.net

FOR ANY QUERIES EMAIL TO

- editorofijpbs@yahoo.com
- editorijpbs@rediffmail.com
- prasmol@rediffmail.com



**HEPATOPROTECTIVE ACTIVITY OF METHANOLIC
EXTRACT OF *MELIA AZEDARACH. L* ON WISTAR RATS**

DR.A.SUMATHI

*Assistant professor, PG and Research department of biotechnology,
Hindusthan College of Arts & Science, Coimbatore-641028,Tamilnadu, India*

ABSTRACT

The objective of the present study appraised the hepatoprotective activity of methanolic extract of *Melia azedarach. L* leaves on Wistar rats. The Methanolic extracts of *Melia azedarach. L* (200mg & 500mg/kg,b.w,p.o) was administered respectively to the animals which were treated with carbon tetrachloride. Its effects on biochemical parameters were compared with standard drug silymarin (100mg/kg,b.w p.o). *Melia azedarach. L* showed prominent reduction of serum enzymes-AST, ALT, ALP, TP & Bilirubin (Aspartate Transaminase, Alanine Transaminase, Alkaline Phosphatase, Total Protein & Total bilirubin) when compared to the control rats. The hepatoprotective effect of *Melia azedarach. L* was comparable with the standard drug Silymarin. It was confirmed through histopathological study. The effect of extracts 500mg/kg was almost equal to that of standard drug Silymarin.

KEYWORDS: *Melia azedarach. L*, carbon tetrachloride, hepatoprotective, Silymarin.



DR.A. SUMATHI

*Assistant professor, PG and Research department of biotechnology,
Hindusthan College of Arts & Science, Coimbatore-641028,Tamilnadu, India*

**Corresponding author*

INTRODUCTION

The liver plays an important role in detoxification and excretion of many endogenous and exogenous compounds. Any damage or impairment to its functions may lead to many health implications. Hepatic dysfunction due to inhalation of hepatotoxin is increasing worldwide.^{1,2} Among the various mechanisms involved in the hepatotoxicity by hepatotoxin, one is oxidative damage through free radical generation.^{3,4} Management of liver disease is still a challenge to the modern medicine. Conventional medicine is now pursuing the use of natural products such as herbs to provide the support that the liver needs on a daily basis.⁵ *Melia azedarach. L* family Meliaceae is from west Asia, It is widely distributed in the Himalayan region between the attitude of 700 to 1000 m. A moderate-Sized deciduous tree 9-12m in height with a cylindrical bole with dark gray bark having shallow longitudinal furrows; leaves are bi-or tripinnate, pinnate opposite or alternate, ovate or lanceolate, serrate, acuminate, glabrous on both surfaces, slightly oblique at the base.⁶ It is also used to cure strangury, amenorrhea, bronchitis leprosy, eczema, asthma & as an antipyretic.⁷ The plant contains alkaloids, flavanoids, steroids, tannins and lycopene content.⁸ In the present study the Hepatoprotective effect of Methanolic extract of *Melia azedarach. L* is investigated in a scientific manner to validate its use as an alternative and complementary herbal drug.

MATERIALS AND METHODS

Collection of plant Material

The leaves of *Melia azedarach. L* were collected from the Western Ghats of Anamalai Hills, Coimbatore district, Tamilnadu and stored at room temperature in a dry place prior to use.

Plant Authentication

The plant was identified and authenticated by the Botanical Survey of India (BSI), Coimbatore, Tamilnadu, India.

Extract Preparation

The dried *Melia azedarach. L* leaves powder (75g) was extracted in a Soxhlet apparatus with 450 ml of 95% ethanol at controlled temperature. The collected extract was concentrated under reduced pressure (<450C) using a vacuum pump for complete removal of the solvent. Pure organic part of the sample thus prepared was stored at 4-50C until used. The extract was then subjected to qualitative phytochemical investigation for the identification of phytoconstituents viz. steroids, alkaloids, glycosides, saponins, tannins, carbohydrates and flavanoids.⁹

Animals

Adult albino (Wistar strain) rats weighing between 160-200gm (2-3 months) were used for the study. The animals were obtained from Medical college of Trichur, Kerala,. The use of animals was approved by the 'Institutional Animal Ethical Committee'. Throughout the experimental period, the animals were housed in cages under room temperature (20±20c); relative humidity (60- 70%) and were exposed to 12:12h of light: dark cycle. The rats were fed with standard laboratory diet supplied by Sai Durga Feeds, Bangalore and water *ad libitum*.

Determination of Acute Toxicity Study

Minimal lethal dose (MLD) in Wistar albino mice in a group of 10 each for each dose was calculated for the extract by Litchfield and Wilcoxon¹⁰ method. The animals were administered oral graded dose of the extract with MLD 2500mg/kg.

Experimental Procedure

The experiment was carried out after getting clearance from the Institutional Animal Ethical Committee. The animals were divided into 5 groups of 6 animals each. The animals from Group I which served as control received vehicle 1%Acacia at a dose of 1mg/kg p.o and olive oil (1ml/kg p.o) for 7 days. Group II-V received 1ml/kg/day p.o of CCl₄ for all 7 days.¹¹ The standard drug Silymarin (100mg/kg p.o.) was administered to Group III animals for 7 days. Group IV & V received a

methanolic extract of *Melia azedarach. L* in the dose for 7 days respectively. The CCl₄, Silymarin & the extracts were administered concurrently to the respective group of animals. On the 7th day, blood was collected through a retro orbital vein and the serum was separated by centrifugation at 2500 rpm for 10 minutes. Serum was used for the assay of hepatic marker enzymes – total protein, total bilirubin, serum aspartate transaminase, serum alanine transaminase, and alkaline phosphatase.¹² Then the animals were sacrificed; liver was dissected immediately and used for histopathological studies.

Histopathological Studies

The tissue of the liver was fixed in 10% formalin and embedded in paraffin wax. Sections of 4-5 μ thickness were made and stained with haematoxylin-eosin. Histological observations were made under light microscope.¹³

Statistical Analysis

The values were expressed as mean \pm SEM. The statistical analysis was carried out by One way Analysis of Variance (ANOVA) followed by Students Newman-keuls test. P values <0.01 were considered significant.

RESULTS

Acute toxicity studies

Melia azedarach. L produces 50% of mortality at 2500 mg/kg. Thus two doses (200 and 500 mg/kg p.o.) which were found to be safe were used for further pharmacological studies.

Biochemical estimations

The results for the effect of *Melia azedarach. L* on serum enzymes ALT, AST, ALP, TP, Bilirubin are shown in Table 1. The administration of ccl₄ resulted in a marked increase of ALT, AST, ALP & Bilirubin levels in serum.

Table 1
Effect of *Melia azedarach. L* leaf extracts on ALT, AST, ALP, TP and Bilirubin

Groups	Treatment	ALT (U/ml)	AST (U/ml)	ALP (U/ml)	TP (g/dl)	Bilirubin (mg/dl)
I	Acacia+Olive oil (1ml+1ml/kg p.o)	54.64 \pm 4.48	42.91 \pm 3.08	35.82 \pm 4.19	6.78 \pm 0.57	0.86 \pm 0.4
II	CCl ₄ (1ml/kg p.o)	107.33 \pm 3.17*	103.11 \pm 3.86*	87.16 \pm 2.97*	2.21 \pm 0.33*	4.16 \pm 1.23*
III	CCl ₄ +Silymarin (100ml/kg p.o)	74.28 \pm 4.16**	67.72 \pm 2.39**	43.92 \pm 1.96**	5.93 \pm 3.9**	1.10 \pm 0.39**
IV	CCl ₄ +M.a-extract (200ml/kg p.o)	69.78 \pm 2.61**	61.59 \pm 2.19**	51.06 \pm 5.29**	3.42 \pm 0.39**	2.26 \pm 0.92**
V	CCl ₄ +M.a-extract (500ml/kg p.o)	62.89 \pm 2.36**	47.64 \pm 2.42**	40.36 \pm 4.17**	6.14 \pm 0.23**	1.10 \pm 0.98**

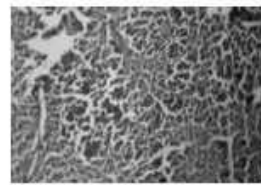
Values are Mean \pm SEM: n=6, by ANOVA followed by student-Newman-keuls test; *p<0.05 vs group-I, **p<0.05 vs group-II: ALT-Alanine Transaminase, AST-Aspartate, Transaminase; ALP-Alkaline Phosphatase; TP-Total protein However, the decrease in total protein level was observed. The toxic effect of CCl₄ was significantly controlled (p<0.01) in the animals treated with Methanolic extract of *Melia azedarach. L* by way of restoration of the levels of liver function biochemistry similar to that of standard drug silymarin. The animals treated with 500 mg/kg of the extract showed significant results which were almost equal to that of silymarin.

Histopathology


Histopathological profile of liver sections of the control group showed normal cellular architecture with distinct hepatic cells, sinusoidal spaces and central vein (Figure 1a). Group II animals exhibited disarrangement of normal hepatic cells with intense centrilobular necrosis, vacuolization of

cytoplasm and fatty degeneration (Figure 1b). The liver sections of the rats treated with methanol extract of *Melia azedarach* and silymarin followed by CCl₄ intoxication showed a sign of protection as it was evident by the absence of necrosis and vacuoles (Figure 1c, 1d & 1e).

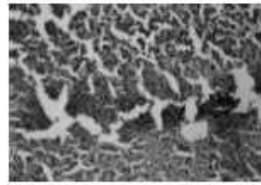
Figure 1
Slides showing histopathology of liver tissues



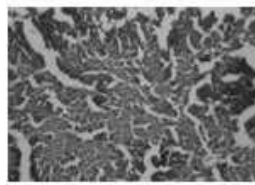
a) Control




b) CCl₄ treated



c) silymarin-treated



d) Methanol extract (200mg/kg) treated



e) Methanol extract (500mg/kg) treated

- a) Section of the liver tissue of control rats showing normal histology*
b) Section of the liver tissue of rats treated with CCl₄ showing necrosis & Fatty vacuole
c) Section of the liver tissue of silymarin-treated rat showing normal hepatocytes & hepatic duct
d) Section of the liver tissue of methanol extract (200mg/kg) treated rat showing normal arrangements of hepatocytes around the central vein
e) Section of the liver tissue of methanol extract (500mg/kg) treated rat showing normal arrangements of hepatocytes around the central vein, absence of necrosis

DISCUSSION

Carbon tetrachloride is one of the most commonly used hepatotoxins in the experimental study of liver diseases.¹⁴ It induces liver cell necrosis and apoptosis and can be used to induce hepatic fibrosis or cirrhosis by repetitive administration.¹⁵ The hepatotoxic effect of carbon tetrachloride is mainly due to its active metabolite, trichloromethyl radical.¹⁶ This activated radical binds covalently to the macromolecules and induces lipid peroxidation and forms lipid peroxides which produce damage to the membrane.¹⁷ The increase in the levels of serum bilirubin reflected the depth of jaundice and the increase in transaminases and alkaline phosphatase which are cytoplasmic in location and released into circulation after cellular damage was the clear indication for the loss of functional integrity of the cell

membrane.^{18,19} Amino transferases are present in high concentration in liver, an important class of enzymes linking carbohydrate and amino acid metabolism. Alanine amino transferase and aspartate amino transferase are well known diagnostic indicators of liver disease. In cases of liver damage with hepatocellular lesions and parenchymal cell necrosis, these marker enzymes are released from the damaged tissues into the blood stream.²⁰ In the present study, the activities of these enzymes were found to increase in the hepatotoxic animals, and were significantly reduced in groups of methanolic extract of *Melia azedarach. L* administered rats as compared to that of toxicant rats. This confirms the protective effect of Methanolic extract of *Melia azedarach. L* against carbon tetrachloride induced hepatic damage. The effect was more

pronounced with 500mg/kg extract. A possible mechanism of the *Melia azedarach* L extract as hepatoprotective may be due to its anti-oxidant effect or inhibition of cytochrome P450.²¹ This might be due to the higher contents of flavonoids present in the extract which could have reduced the accumulation of toxic CCl₃ derived metabolites. Intense centrilobular necrosis and vacuolization were found in the histopathological examination of the liver section of the rats treated with toxicant. The rats treated with silymarin and extracts with toxicant showed protection against those toxicants. This is confirmed from the evident of formation of normal hepatic cords and absence of necrosis and vacuoles.

CONCLUSION

Hepatoprotective activity of the methanolic extracts (200.500mg/kg) of *Melia azedarach* L was studied. In this study, the drug treated animals showed decreased serum enzymes

like ALT,AST,ALP and Bilirubin. This confirms the protective effect of Methanolic extract of *Melia azedarach* against carbon tetrachloride induced hepatic damage. A possible mechanism of the *Melia azedarach* extract as hepatoprotective may be due to its anti-oxidant effect or inhibition of cytochrome P450. This might be due to the higher contents of flavonoids present in the extract which could have reduced the accumulation of toxic CCl₃ derived metabolites. Histopathological examination of the liver section of the rats treated with toxicant showed intense centrilobular necrosis and vacuolization. The rats treated with silymarin and extracts along with toxicant showed signs of protection against these toxicants to a considerable extent as evident from formation of normal hepatic cords and absence of necrosis and vacuoles. Thus it was concluded that the extract exhibited significant dose dependent hepatoprotective activity. The effect of the extract 500mg/kg was almost equal to that of standard drugs used.

REFERENCES

1. Reddy P B, Reddy C K, Rambhau D et al. Indian J Pharm Sci 1993; 55:134.
2. Preussmann R; Hepato carcinogens as potential risk for human liver cancer. In: Remmer H, Bolt HM, Bannasch P, eds. Primary liver tumors. Lancaster, MTP press, 1978;11-29.
3. Montesano R, Kirby G M; Chemical carcinogens in human liver cancer. In: Brechot, eds. Primary liver cancer- Etiological and progression factors. CRC, Boca Raton, 1994; 57-77.
4. DeLeve L D, Kaplowitz N; Mechanisms of drug induced liver disease. Gastroenterol clin N Am 1995; 24:787-810.
5. Sherlock S, Dooley J; Disease of liver & biliary system. Blackwell scientific publications 2002; 11; 322-356.
6. Warriar, P. K., Nambiar, V. P. K. and Ramankutty, C. (1933). Indian Medicinal plants: a compendium of 500 species, Orient Longman Ltd., Madras, 4 : 10.
7. Oelrichs, P. B., Hill, M. W., Vallely, P.J., Macleod, J.K. and Molinski, T.F. (1985). The chemistry and pathology of Melia toxins A and B constituents from the fruit of *Melia azedarach* L. var. australasica, p. 387-394. In : Seawright, A.A., Hegarty, M.p>, James, L.f. et al. (ed.) Plant Toxicology. Queensland Poisonous Plants Committee, Yeerongpilly, Australia.
8. Gerster, H. (1997). Potencial role of β -carotene in the prevension of cardiovascular disease. *International J. Vit. Nutr. Res.*, 61: 277-291.
9. Shas B S, Quadry J S; A Text Book of Pharmacognosy. B.S.Prakashan, New Delhi 1980; 16&24.
10. Litchfield J T, Wilcoxon F; A simplified method of evaluating dose-effect experiments. J Endocriol 1943; 33:297-299.
11. Jaiprakash B, Aland R, Karadi R V et al. Hepatoprotective activity of fruit pulp of

- Balanites aegyptiaca*. Indian Drugs 2003; 40:296-297.
12. Mankani K L, Jagadeesh Singh S D, Manohara Y N et al. Evaluation of hepatoprotective activity of stem bark of *Pterocarpus marsupium* Roxb. I J Pharmacol 2005;37:165-168.
 13. Sethuraman M G, Lalitha K G, Raj Kapoor B; Hepatoprotective activity of *Sarcostemma brevistigma* against carbon tetrachloride induced hepatic damage in rats. Current Science 2003;84:1186-1187.
 14. Johnson D E, Kroening C; Mechanism of early Carbontetrachloride toxicity in cultured rat hepatocytes, Pharmacol Toxicol 1998;83:231-9 17.
 15. Shi G F, Q Li; Effects of oxymetrine on experimental hepatic fibrosis and its mechanism *in-vivo*. World J Gastroenterol 2005;11:268-271.
 16. Srivastava S P, Chen N O, Holtzman J L; The *in-vitro* NADPH dependent inhibition by ccl4 of the ATP dependent calcium uptake of hepatic microsomes from male rats-Studies on the mechanism of inactivation of the hepatic microsomal calcium pump by the ccl3. radical. J biol chem 1990;265:8392-9
 17. Mujeep M, Aeri V, Bagri P et al. Hepatoprotective activity of methanolic extract of *Tylophora indica* leaves. I J Green Pharmacy 2009;125-127.
 18. Saraswat B, Visen P K, Patnaik G K et al. Anticholestic effect of picroliv, active hepatoprotective principle of *Picrorhiza kurrooa* against carbon tetrachloride induced cholestatis. Indian J Exp Biol 1993; 31:316-8.
 19. Sallie R, Tredger J M, William R; Drugs and the liver. Part I. Testing liver function. Biopharm Drug Disp 1991; 12:251-259.
 20. Chaudhari B P, Chaware V J, Joshi Y R et al. Hepatoprotective activity of Hydroalcoholic extract of *Momordica charantia* Linn. leaves against Carbon tetrachloride induced Hepatopathy in Rats. I J ChemTech Res 2009; 1(2):355-358.
 21. Recknagel R O, Glende E A, Dolak J A et al. Mechanisms of carbon tetrachloride toxicity. Pharmacol Ther 1989; 43:139-154